

BRIEF ARTICLE

Erosive Pustular Dermatitis of the Scalp Treated with Serial Debridement: Case Report

Brenna M. Aran, BA,¹ Lydia A. Luu, MD,² R. Hal Flowers, MD²

¹ University of Virginia School of Medicine, Charlottesville, Virginia

² Department of Dermatology, University of Virginia Medical Center, Charlottesville, Virginia

ABSTRACT

An 82-year-old man with a past medical history of numerous non-melanoma skin cancers (NMSCs), including unresectable squamous cell carcinoma of the right temple treated with radiation therapy and cemiplimab, presented with worsening erosive pustular dermatosis of the scalp (EPDS). This had initially onset four years prior in the setting of 5-fluorouracil and photodynamic therapy for actinic keratoses. He had failed topical ultra-potent steroids, tacrolimus, and dapsons as well as oral dapsons, doxycycline, and acitretin. The condition's chronicity and radiation to the area likely exacerbated his EPDS. We pursued serial debridement, followed by clobetasol propionate 0.05% ointment twice daily. The patient reported marked improvement with stable condition between treatments. Upon better control of his EPDS, a suspicious ulcerative lesion under a previously affected area was identified and biopsied, revealing atypical fibroxanthoma. EPDS is an inflammatory dermatosis characterized by pustules, erosions, and crusting, often caused by sun damage, local trauma, and topical medications. First-line treatment is topical corticosteroids. We show that serial debridement is effective for treating recalcitrant EPDS. We emphasize the importance of maintaining adequate control of EPDS to avoid masking suspicious lesions, as the patient demographic affected by EPDS is at high risk for NMSCs.

INTRODUCTION

Erosive pustular dermatosis (EPD) is a rare dermatologic condition of the scalp characterized by pustules, erosions, and thick yellow-brown crusting and often resulting in scarring alopecia.¹ Risk factors for EPD include sun damage and local trauma including physical injury, burns, surgery, and procedures; topical medications and autoimmune conditions including Hashimoto's thyroiditis, Takayasu's arteritis, autoimmune hepatitis, rheumatoid arthritis, and myasthenia gravis have also been

associated.² EPD is most commonly seen in elderly women but affects men as well, and occasionally children.²

The histopathology is nonspecific but may show hyperkeratosis, parakeratosis, and diffuse mixed inflammatory infiltrate, and is thought to be inflammatory with resulting cutaneous atrophy.³⁻⁶ Typical treatments for EPD include ultrapotent topical steroids, topical tacrolimus, and topical dapsons.⁷

CASE REPORT

September 2023 Volume 7 Issue 5

An 82-year-old man with a past medical history of numerous non-melanoma skin cancers (NMSCs), including unresectable squamous cell carcinoma (SCC) of the right temple treated with radiation therapy and cemiplimab, presented with worsening erosive pustular dermatosis of the scalp (EPDS). Initial onset was four years prior in the setting of topical 5-fluorouracil and photodynamic therapy for actinic keratoses. He had failed topical ultrapotent steroids, topical tacrolimus and topical dapsone, as well as oral dapsone, doxycycline, niacinamide, and acitretin. He presented to clinic following a course of radiation therapy for the abovementioned squamous cell carcinoma of the right temple. Physical exam revealed a very large, eroded plaque with overlying thick yellow-brown crust covering the right scalp and right temple (**Figure 1**). Serial debridement was pursued every 3 weeks, followed by clobetasol propionate 0.05% ointment twice daily. The patient experienced marked improvement, without subsequent progression between treatments.

Upon better control of his EPDS, a suspicious ulcerated plaque under a previously affected area was identified and biopsied (**Figure 2**). The biopsy revealed dermal proliferation of highly atypical spindle-shaped cells, histiocyte-like cells, and clear to foamy cells which had severe nuclear pleomorphism and prominent mitotic activity. Immunohistochemical stains showed the lesional cells to be negative for p40, S100, MelanA, desmin, CD34, and ERG, and a diagnosis of atypical fibroxanthoma was made.

DISCUSSION

EPDS is a rare condition that can be caused by dermatologic therapies including radiation,

photodynamic therapy, and topical 5-fluorouracil, as in the present case.^{2,8} Awareness of EPDS is crucial for dermatologists, because many medications and procedures provided by dermatologists may be associated with EPDS.²

This patient's EPDS was complicated by locally advanced, unresectable SCC of the right temple and cheek treated with radiation therapy, which likely exacerbated the condition. His EPDS did not respond to usual therapies such as topical ultrapotent steroids, tacrolimus, and dapsone. The chronicity of this patient's EPDS and the cutaneous atrophy from his long-term use of topical steroids likely made his condition more difficult to treat over time, as atrophy is involved in the pathogenesis of EPDS.⁷ Here, serial debridement is shown to be an effective treatment option for recalcitrant EPDS, as it greatly reduced the disease burden for this patient.

Debridement has previously been used as part of EPDS management with varying success. In one case, a patient with severe ulcerating EPDS, superimposed soft tissue infection, and possible skull osteomyelitis was unsuccessfully treated with multiple rounds of intravenous (IV) and oral antibiotics but improved following three serial debridements and topical steroids.⁹ In a second, similar case of EPDS with superimposed soft tissue infection and chronic skull osteomyelitis, the patient was treated with a single debridement; however, this patient did not experience improvement.¹⁰ These cases highlight the need for further study of the role of debridement for EPDS.

Therapies that the present patient has not tried that may be effective for EPDS include photodynamic therapy and fractional ablative laser therapy. However, these treatments

have also been implicated as causes of EPDS, so their use remains controversial.¹¹ There have also been reports of oral JAK inhibitors used in EPDS, but this was contraindicated for this patient with active SCC.¹²

EPDS can be easily confused with other dermatologic conditions such as SCC and actinic keratosis (AK), and they are not mutually exclusive. EPDS, SCC, and AKs all can present with hyperkeratosis and erosion as a crusted plaque.¹³ Because patients with EPDS are also at high risk for NMSCs, it is important to maintain adequate control of EPDS to avoid masking suspicious lesions, such as the atypical fibroxanthoma discovered in this patient.

Conflict of Interest Disclosures: None

Funding: None

Corresponding Author:

Brenna M. Aran, BA
University of Virginia, Department of Dermatology
PO Box 800718, Charlottesville, VA 22908-0718
Email: bd5bm@virginia.edu

References:

1. Pye R j., Peachey R d. g., Burton J I. Erosive pustular dermatosis of the scalp. *Br J Dermatol.* 1979;100(5):559–66.
2. Karanfilian KM, Wassef C. Erosive pustular dermatosis of the scalp: causes and treatments. *Int J Dermatol.* 2021 Jan;60(1):25–32.
3. Lee KH, Carley SK, Kraus CN, Mesinkovska NA. Treatment of erosive pustular dermatosis: a systematic review of the literature. *Int J Dermatol.* 2020;59(7):770–86.
4. Patton D, Lynch PJ, Fung MA, Fazel N. Chronic atrophic erosive dermatosis of the scalp and extremities: A recharacterization of erosive pustular dermatosis. *J Am Acad Dermatol.* 2007 Sep;57(3):421–7.
5. Shavit E, Alkallabi M, Alavi A. Scalp ulcers – differential diagnoses that should be sought! *Int J Dermatol.* 2019;58(11):1283–92.
6. Starace M, Loi C, Bruni F, Alessandrini A, Misciali C, Patrizi A, et al. Erosive pustular dermatosis of the scalp: Clinical, trichoscopic,

- and histopathologic features of 20 cases. *J Am Acad Dermatol.* 2017 Jun 1;76(6):1109-1114.e2.
7. Junejo MH, Kentley J, Rajpopat M, Tan XL, Mohd Mustapa MF, Harwood CA. Therapeutic options for erosive pustular dermatosis of the scalp: a systematic review. *Br J Dermatol.* 2021 Jan;184(1):25–33.
8. Trüeb RM, Krasovec M. Erosive pustular dermatosis of the scalp following radiation therapy for solar keratoses. *Br J Dermatol.* 1999 Oct;141(4):763–5.
9. Din RS, Tsiaras WG, Mostaghimi A. Two Cases of Severe Erosive Pustular Dermatitis Mimicking Infection. *Wounds Compend Clin Res Pract.* 2018 Aug;30(8):E84–6.
10. Marsh RL, Spohn GP, Kaffenberger JA. Erosive pustular dermatosis of the scalp. *Dermatol Online J.* 2020 Aug 15;26(8):13030/qt8ks9j8sv.
11. Starace M, Iorizzo M, Trüeb RM, Piccolo V, Argenziano G, Camacho FM, et al. Erosive pustular dermatosis of the scalp: a multicentre study. *J Eur Acad Dermatol Venereol JEADV.* 2020 Jun;34(6):1348–54.
12. Leung N, Eldik H, Ramirez MR, Sodha P. Oral Tofacitinib Treatment of Erosive Pustular Dermatitis of the Scalp. *JAMA Dermatol.* 2019 Jun 1;155(6):752–4.
13. Deb PQ, Cai D, Bhate C. Erosive pustular dermatosis of the scalp may not be mutually exclusive with other dermatoses. *Clin Dermatol.* 2021 Jun;39(3):489–92.

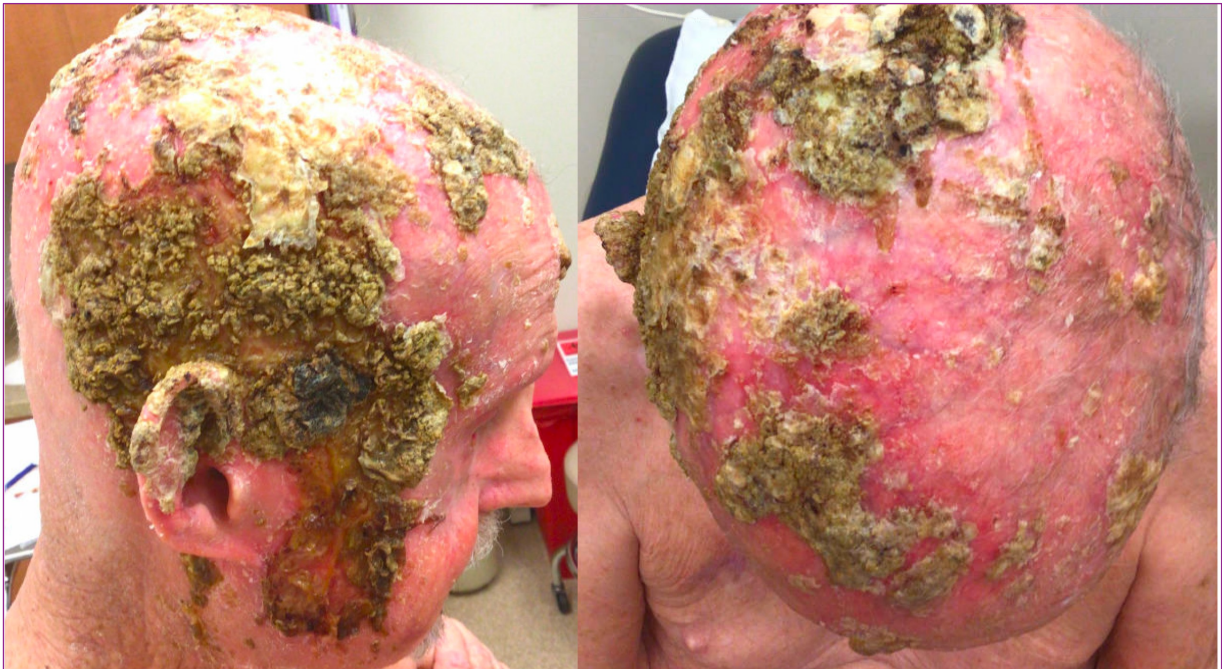

Figure 1. Before first debridement. Large, eroded plaque with overlying yellow-brown crust on the right scalp and temple consistent with EPDS.

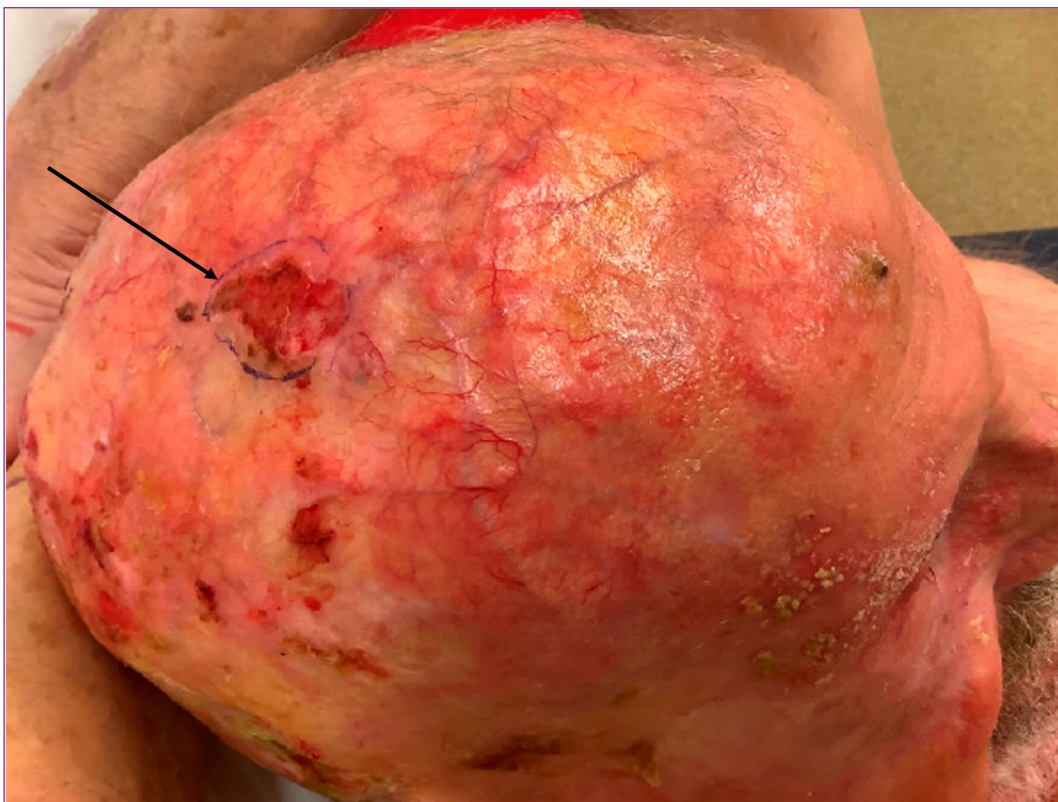


Figure 2. Right frontal scalp following three serial debridements with an ulcerative lesion, later biopsied and identified as atypical fibroxanthoma.