

RESEARCH LETTER

Representation of Skin Color, Disease Severity, and Anatomic Location in Hidradenitis Suppurativa Images

Devea R. De, MD¹, Sarah E. Park, BA², Terri Shih MD³, Vivian Y. Shi, MD⁴, Jennifer L. Hsiao, MD⁵

¹ Morristown Medical Center, Morristown, NJ, USA

² David Geffen School of Medicine, University of California, Los Angeles, CA, USA

³ Kaiser Los Angeles Medical Center, Los Angeles, CA, USA

⁴ University of Arkansas for Medical Sciences, Department of Dermatology, Little Rock, AR, USA.

⁵ University of Southern California, Department of Dermatology, Los Angeles, CA, USA

ABSTRACT

Introduction: Hidradenitis suppurativa (HS) is an inflammatory dermatosis disproportionately affecting patients of color. We evaluated characteristics of HS images in dermatology online image resources and textbooks.

Methods: Images of HS were collected in December 2021 from online and textbook sources. Data regarding anatomic region, Hurley stage, and Fitzpatrick skin tone (FST) were collected and analyzed.

Results: 318 images remained after exclusion criteria. VisualDx contained the highest number of dark skin (FST V-VI) images (59%, 47/79), followed by Google (4%, 2/52) and DermNetNZ (4%, 4/100). In textbook sources, dark skin represented 25% (4/16) of images. Across sources, 47% (151/318) of images represented Hurley stage 2, followed by 32% (101/318) stage 3, and 21% (66/318) stage 1. The axilla (49%, 156/318) was the most common anatomic location featured, followed by the groin (18%, 58/318) and breast/chest (9%, 28/318). Involvement of non-classic locations was represented in 3% (8/318) of images. There was a positive correlation between higher Hurley stage and darker skin ($r=0.26$, $p<0.05$).

Conclusion: Overall, there is underrepresentation of dark skin tones, “non-classic” anatomic locations, and mild HS which may lead to missed opportunities for patient education and dermatology training. Dermatologists should take the lead to improve image diversity across educational resources.

INTRODUCTION

Hidradenitis suppurativa (HS) is a debilitating inflammatory skin condition disproportionately affecting skin of color (SOC) patients. There is a paucity of data examining the diversity of HS images. Herein, we examine characteristics of HS

images in online dermatology image resources and dermatology textbooks.

METHODS

In December 2021, HS images were collected from online dermatology image resources (Google images, dermatology

July 2024 Volume 8 Issue 4

websites, and image banks) and dermatology textbooks (**Figure 1**). Data regarding anatomic region, Hurley stage, and Fitzpatrick skin type (FST) were collected. Correlation between Hurley stage and FST was evaluated using Pearson's correlation coefficient. Statistical analyses were conducted in R-4.1.0.

RESULTS

Out of 385 images, 318 (302 online resources, 16 textbooks) remained after exclusion criteria (**Table 1**). VisualDx contained the highest number of dark skin (FST V-VI) images (59%, 47/79), followed by Google images (4%, 2/52), DermNetNZ (4%, 4/100), UpToDate (0%, 0/8), and DermNet (0%, 0/64). Of the free image sources studied (Google images, DermNetNZ, Dermnet), only 3% (6/215) displayed dark skin. For textbook sources, dark skin represented 25% (4/16) of images. Of the textbook sources, only Fitzpatrick had dark skin representation (40%, 4/10), and Lookingbill & Marks had no HS images. Only 4% (13/318) of all images represented FST VI.

Across sources, 47% (151/318) of images represented Hurley stage 2, followed by 32% (101/318) stage 3, and 21% (66/318) stage 1. The axilla (49%, 156/318) was the most common anatomic location featured across all sources followed by the groin (18%, 58/318) and breast/chest (9%, 28/318). Involvement of non-classic (non-axilla, breast, groin, buttock, inner thigh) locations was represented in 3% (8/318) of images. There was a positive correlation between higher Hurley stage and darker skin ($r=0.26$, $p<0.05$).

DISCUSSION

Our study found underrepresentation of dark skin tones, "non-classic" anatomic locations, and mild disease in HS images in online resources and popular dermatology textbooks.

HS disproportionately affects SOC patients; however, this is not reflected in the poor diversity of skin tone representation of HS images in educational resources. Google has been found to be the most accessed search engine by dermatology patients and is also commonly used by physicians.^{1,2} Thus, the lack of skin tone diversity in Google images is particularly concerning and may contribute to missed diagnoses and poor health outcomes.³ VisualDx has the highest proportion of dark skin images but requires a subscription, so is less accessible to patients. The lack of skin tone diversity in widely used dermatology textbooks is a learning gap for dermatology trainees.

The limited representation of mild HS in educational sources may hinder early diagnosis. The positive correlation between Hurley stage and FST suggests there are fewer darker skin images of mild disease, which may further contribute to delayed diagnoses in darker skin-toned individuals disproportionately. The scarcity of images of "non-classic" HS locations may lead to missed diagnoses in patients with atypical HS. Adequate representation of early HS lesions and involvement of non-intertriginous sites is paramount to promoting early recognition of HS, especially as online resources are used by patients and frontline healthcare providers who are often in the position to make the initial diagnosis.

Our findings are consistent with other studies demonstrating the underrepresentation of SOC images in dermatologic conditions across internet sources and educational

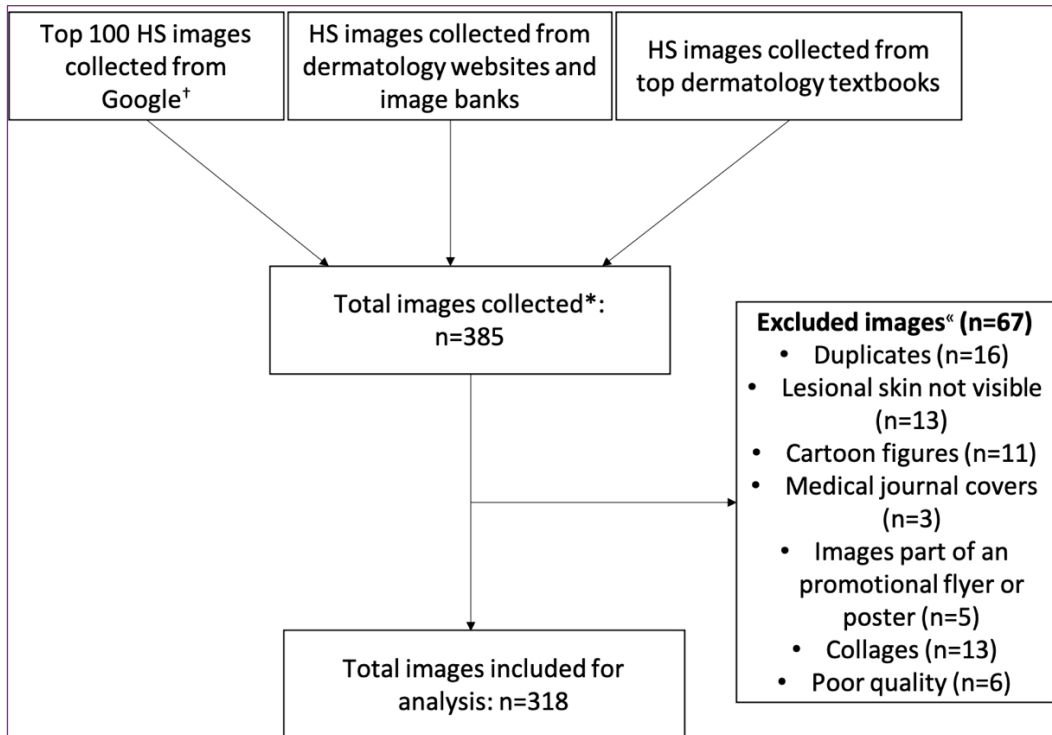


Figure 1. Schematic depicting selection of hidradenitis suppurativa images from online and textbook sources.

†Google images were searched with the term “Hidradenitis suppurativa” using the Google Chrome “Incognito” mode, with location tracking blocked and browsing data, cookies, and cached images cleared.

*The search term “hidradenitis suppurativa” was used to search all resources.

« Images were excluded if they were duplicates within the same source, non-color images, images without visible lesional skin, cartoon images, medical journal covers, part of a promotional flyer, collages, or of poor quality.

materials, underscoring the global need for increasing image diversity.⁴

Limitations of this study are other educational sources not included in our analysis. The lack of HS image diversity translates into missed opportunities for patient education and dermatology training, potentially impacting patient outcomes. Dermatologists should take the lead to improve image diversity in online and textbook resources to reflect the demographics of the HS population.

Conflict of Interest Disclosures: JLH is on the Board of Directors for the Hidradenitis Suppurativa Foundation, has served as a consultant for Aclaris, AbbVie, Boehringer Ingelheim, Incyte, Novartis, and UCB; as a speaker for AbbVie; as an investigator for Amgen, Boehringer Ingelheim, and Incyte. VYS is on the board of directors for the Hidradenitis Suppurativa Foundation (HSF), an advisor for the National Eczema Association, is a stock shareholder of Learn Health and has served as an advisory board member, investigator, speaker, and/or received research funding from Sanofi Genzyme, Regeneron, AbbVie, Genentech, Eli Lilly, Novartis, SUN Pharma, LEO Pharma, Pfizer, Incyte, Boehringer Ingelheim, Alumis Aristeia Therapeutics, Menlo Therapeutics, Dermira, Burt's Bees, Galderma, Kiniksa, UCB, Target-PharmaSolutions, Altus Lab/cQuell, MYOR, Polyfins Technology, GpSkin and Skin Actives Scientific. DRD, SP, TS have no conflicts of interest to disclose.

Funding: None

Corresponding Author:

Jennifer L. Hsiao, MD
 1441 Eastlake Ave, Ezralow Tower, Suite 5301
 Los Angeles, CA 90033-9174
 Phone: 310-601-3367
 Email: j.hsiao.publications@gmail.com

References:

1. Gantenbein L, Navarini AA, Maul LV, Brandt O, Mueller SM. Internet and social media use in dermatology patients: Search behavior and impact on patient-physician relationship. *Dermatol Ther* [Internet]. 2020 Nov [cited 2022 Feb 19];33(6). Available from: <https://onlinelibrary.wiley.com/doi/10.1111/dth.14098>
2. Screen to Script: The Doctor's Digital Path to Treatment [Internet]. [cited 2022 Feb 19]. Available from: https://www.thinkwithgoogle.com/_qs/documents/692/the-doctors-digital-path-to-treatment_research-studies.pdf
3. Rick JW, Thompson AM, Fernandez JM, Maarouf M, Seivright JR, Hsiao JL, et al. Misdiagnoses and barriers to care in hidradenitis suppurativa: A patient survey. *Australas J Dermatol*. 2021 Nov;62(4):e592–4.
4. Kurtti A, Austin E, Jagdeo J. Representation of skin color in dermatology-related Google image searches. *J Am Acad Dermatol*. 2022 Mar;86(3):705–8.

Table 1. Characteristics of hidradenitis suppurativa images in online and textbook sources.

	Skin tone [§]			Hurley Staging [^]			Anatomical location						
	Total images N	Dark n (%)	Light n (%)	Hurley stage 1 n (%)	Hurley stage 2 n (%)	Hurley stage 3 n (%)	Axilla n (%)	Breast/Chest n (%)	Groin n (%)	Buttock s/perianal n (%)	Inner Thighs n (%)	Other* n (%)	Inconclusive n (%)
Online Sources^{&}													
Dermnet	63	0 (0)	63 (100)	21 (33)	34 (54)	8 (13)	24 (38)	10 (16)	13 (19)	4 (6)	0 (0)	1 (2)	11 (17)
DermNet NZ	100	4 (4)	96 (96)	24 (24)	53 (53)	19 (19)	35 (35)	13 (13)	20 (20)	9 (9)	3 (3)	2 (2)	18 (18)
Google Images	52	2 (4)	50 (96)	12 (23)	23 (44)	17 (33)	38 (73)	3 (6)	3(6)	2 (4)	1 (2)	2 (4)	3 (6)
UpToDate	8	0 (0)	8 (100)	2 (25)	4 (50)	2 (25)	3 (38)	1 (13)	2 (25)	1 (13)	0 (0)	0 (0)	1 (13)
VisualDx	79	47 (59)	32 (41)	6 (8)	31 (39)	42 (53)	46 (58)	1 (1)	17 (22)	9 (11)	1 (1)	3 (4)	2 (3)
Textbooks[‡]													
Andrews	2	0 (0)	2 (100)	0 (0)	0 (0)	2 (100)	1 (50)	0 (0)	1 (50)	0 (0)	0 (0)	0 (0)	0 (0)
Bologna	4	0 (0)	4 (100)	0 (0)	2 (50)	2 (50)	2 (50)	0 (0)	0 (0)	1 (25)	0 (0)	0 (0)	1 (25)
Fitzpatrick	10	4 (40)	6 (60)	1 (10)	2 (20)	7 (70)	7 (70)	0 (0)	2 (20)	1 (10)	0 (0)	0 (0)	0 (0)
Lookingbill & Marks	0	-	-	-	-	-	-	-	-	-	-	-	-
Total	318	57 (18)	261 (82)	66 (21)	151 (47)	101 (32)	156 (49)	28 (9)	58 (18)	27 (8)	5 (2)	8 (3)	36 (11)

§ Images were categorized as light (FST I-IV) or dark (FST V-VI). FST for each image was graded by two independent reviewers (DRD, SEP) with any discrepancies resolved by a third reviewer (JLH).

^ Hurley stage was graded by a board-certified dermatologist (JLH)

* Includes face, neck, abdomen, sacrum

& Online sources were accessed the week of December 5th, 2021

« UpToDate and VisualDx required paid subscriptions to access content

‡ Most recent editions (Andrews 13th edition ISBN: 9780323547536, Bologna 4th edition ISBN: 9780702062759, Fitzpatrick 9th edition ISBN: 9780071837798, Lookingbill and Marks 6th edition ISBN: 9780323430401)