

In-Depth Reviews

Clinical Manifestations and Management Considerations of Psoriasis Affecting the Nail Unit

Parth N. Desai BS^a, James Q. Del Rosso DO^{b,c,d}, Mark G. Lebwohl MD^e

^aMercer University School of Medicine, Macon, GA

^bTouro University, Henderson, NV

^cJDR Dermatology Research, Las Vegas, NV

^dDermatology and Cutaneous Surgery, Thomas Dermatology, Las Vegas, NV

^eDepartment of Dermatology, Icahn School of Medicine at Mount Sinai, New York, NY

ABSTRACT

Psoriasis is a chronic, inflammatory disease with a diverse array of clinical manifestations involving the skin, joints, and nails. Of these, nail psoriasis is a frequently overlooked, yet important complication of psoriasis which can cause significant physical and psychological distress to a patient. Psoriasis affecting the nail unit can pose both diagnostic and therapeutic challenges to physicians due to its clinical heterogeneity, the multitude of available treatment options, and the general lack of high-quality research on the subject. In order to aid the practicing clinician in appropriate diagnosis and treatment of nail psoriasis, this review provides an overview of the epidemiological, clinical, and pathophysiologic features of the disease, while also attempting to develop a rationale for effective medical management of the condition.

INTRODUCTION

“The name of the disease, spiritually speaking, is Humiliation.” Thus reads the poignant description of psoriasis by John Updike, a renowned author and life-long victim of the disorder.¹ Originally described as a form of leprosy, psoriasis is a chronic, relapsing-remitting, inflammatory skin disease commonly presenting with well-demarcated silver and erythematous scaling plaques, particularly on extensor surfaces, which can be pruritic or painful.² The worldwide disease prevalence is estimated to be 2-3%, with about 7.4 million people in the

United States suffering from the disease.^{3,4} The pathogenesis of psoriasis is characterized by T-cell activation due to an initial trigger (trauma, infection, drugs, stress), with subsequent cytokine-mediated epidermal hyperproliferation, neovascularization, and inflammation.⁵ Psoriasis has a great deal of interpatient variability in its manifestations, symptomatology, and in its symptom severity. It has several phenotypically distinct, though sometimes overlapping,

variants including plaque, guttate, inverse, pustular, and erythrodermic.²

Among the myriad manifestations of psoriasis, nail involvement is an oft-overlooked, yet extremely important complication. At any given time, between 50-66% of psoriasis patients have nail manifestations, with a lifetime prevalence of 80-90%.^{6,7} Isolated nail psoriasis is present in 5-10% of patients.^{8,9} Though the degree of nail involvement and types of nail changes present varies among patients, in many cases, nail psoriasis can cause disability by compromising the normal structure and function of the nail. A healthy fingernail, not only protects the distal digits, but is crucial for the fine sensory capabilities and manual dexterity of the fingertips via transference of opposing pressure to the palmar surface of the dorsal phalanx.¹⁰ In many societies, nails are an important aesthetic accessory, and the focus of an array of cosmetic products and services. Nail psoriasis interferes with these various functions, underscoring the importance of appropriate treatment to restore these functions, and alleviate physical and psychosocial distress to the patient.¹¹

EMERGENCE OF CLINICAL FEATURES OF NAIL PSORIASIS

The human nail consists of the nail matrix, nail bed, nail plate, nail folds (proximal and lateral), eponychium and hyponychium (Figure 1).¹⁰ Within the nail unit, psoriasis manifests differently based on the relative

involvement of psoriatic inflammation affecting the nail matrix and/or the nail bed.

The nail matrix produces most of the hard, outer-layer of the nail plate (fingernail). The nail matrix is subdivided into dorsal, intermediate, and ventral zones consisting of 2-3 layers of actively dividing basal keratinocytes which propel newly formed cuboidal keratinocytes distally in the direction of nail growth. These cuboidal cells are progressively flattened as they migrate, eventually losing their nuclei and condensing tightly into *onychocytes*, which become the nail plate.¹² *Psoriatic involvement of the nail matrix* causes aggregation of parakeratotic cells in the nail plate and other areas of the nail unit, thereby disrupting the normal process of keratinization and causing characteristic nail changes seen in psoriasis including pitting, leukonychia, crumbling, red spots in the lunula, transverse grooves, and trachyonychia.¹³ These changes are summarized in Figure 2.

The nail bed produces a portion of the innermost, ventral layer of the nail plate by contributing keratinocytes which interlock securely to their corresponding dermal rete ridges. This creates the tight adhesive bond holding the nail plate to nail bed, which continues from the eponychium to the hyponychium.¹² *Psoriatic involvement of the nail bed* leads to the development of onycholysis, salmon patches (oil drops), subungual hyperkeratosis, and splinter hemorrhages.¹³ These changes are summarized in Figure 3.

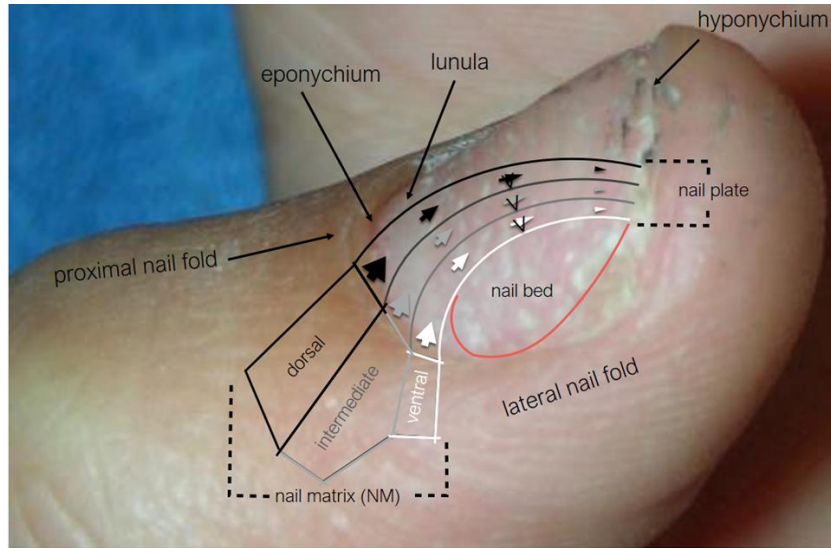


Figure 1. Nail unit anatomy superimposed on a psoriatic nail.

Manifestation	Pathology	Examples
Pitting	These are superficial indentations caused by psoriatic disruption of the dorsal nail matrix leading to parakeratotic cells being incorporated into the outer layers of the nail plate. As the nail grows, these cells slough off and leave depressions in the nail.	
Leukonychia	These are white marks characteristic of psoriatic involvement of the intermediate and ventral nail matrix which form the middle and deeper layers of the nail plate. In this case, the interiorly trapped parakeratotic cells, cannot slough away and are internally desquamated turning white.	
Red spots in the lunula	The lunula, or the white semicircular areas most visible on the thumbs, may turn spotted and erythematous due to psoriatic lesions within the intermediate and ventral nail matrix.	
Nail plate crumbling	Extensive psoriatic lesions involving all three layers of the nail matrix lead to the production of a brittle, crumbly nail plate due to structural incorporation of parakeratotic cells and cellular debris.	

Figure 2. Nail matrix psoriatic manifestations visible on the nail plate¹²




Manifestation	Pathology	Examples
Onycholysis	<p>Onycholysis or nail separation, can occur due to psoriasis induced parakeratosis of the nail bed, compromising the otherwise stable bond joining the nail bed to the nail plate. When this occurs distally at the hyponychium, air enters creating the white appearance of the nail seen. Colonization by <i>Pseudomonas aeruginosa</i> can result in green discoloration (arrow).</p>	
Salmon patch (oil drop)	<p>When psoriatic involvement disrupts the nail bed more proximally, leaving the hyponychium intact, focal onycholysis occurs. This allows for the entrapment of cellular debris in the gap between nail bed and nail plate creating a yellow or white appearance.</p>	
Subungual hyperkeratosis	<p>Due to the build-up of cells underneath the nail plate that have not undergone desquamation. The amount to which the nail plate is lifted upward is based on the degree of psoriatic activity within the nail bed.</p>	
Splinter Hemorrhages	<p>Within the longitudinally aligned epidermal ridges, lie tiny capillaries which rupture and fill the parallel epidermal ridge to create the "splinter" appearance.</p>	

Figure 3. Nail matrix psoriatic manifestations visible on the nail plate¹³

CLINICAL RELEVANCE OF EARLY DIAGNOSIS

Aside from an obvious value early diagnosis and treatment has in preventing nail deterioration and long-term sequelae, there is also growing evidence that psoriatic nail changes may be a predictor of psoriatic arthritis. While the lifetime risk for a psoriasis patient to develop psoriatic arthritis is only 11-40%, psoriatic nail changes are present in about 69-80% of psoriatic arthritis patients.¹⁷⁻²⁰ Of note, a human leukocyte antigen (HLA) locus study of 369 patients done in 2002 showed that the HLA-Cw6 positive patients are more likely to present with extensive plaque psoriasis without nail changes, while HLA-Cw6 negative patients more commonly present with dystrophic nail changes and psoriatic arthritis.²¹ As further research is conducted, recognition of psoriatic nail changes may eventually assist in early diagnosis and disease modifying treatment of psoriatic arthritis. This is critical to slowing the progression of the debilitating disease and preventing the irreversible, deforming joint complications associated with it.²²

APPROACH TO DIAGNOSIS OF NAIL PSORIASIS

Diagnosis of nail involvement in a psoriasis patient is made clinically, based on the presence of characteristic physical exam findings. (Note: It is crucial that the patient remove any nail polish prior to examination as the polish can obscure observation of the lesions.) Examination for psoriatic nail changes can be done using the naked eye, a hand lens, or dermatoscope.¹³ However, the characteristic nail changes seen in psoriasis may also be found in a number of other conditions, thus potentially

complicating the diagnostic evaluation. The differential diagnosis for nail psoriasis includes: onychomycosis, yellow nail syndrome, lichen planus, pachyonychia congenita, alopecia areata (pitting), and atopic dermatitis. Of these, particular attention must be made to differentiate nail psoriasis from onychomycosis due to overlapping presentations. It is likewise important to recognize when both pathologies are present comorbidly, based on reports from multiple studies showing that 27-62% of psoriasis patients also have co-existing onychomycosis.¹⁴⁻¹⁵ If both conditions are present, co-treatment may be required.

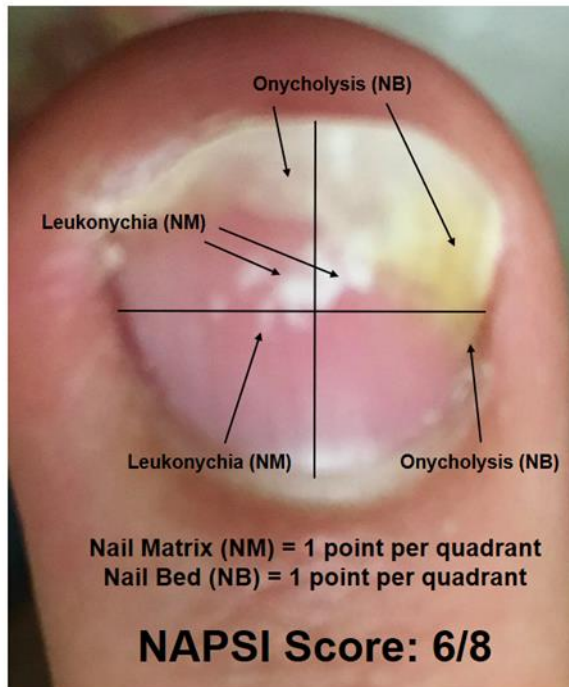
Biopsy is rarely necessary to confirm diagnosis of nail psoriasis in more complex cases, such as the estimated 5-10% of patients with isolated nail psoriasis.⁸⁻⁹ However, it should be considered a last resort due to the potential associated complications, particularly when biopsy of the matrix is needed. In a study of 22 nail psoriasis patients who underwent nail biopsy, a definitive diagnosis of psoriasis was possible in only 55% of cases. Unfortunately, of the 22 patients biopsied, 44% developed scarring or reduced nail width from the procedure and 9% developed biopsy site infections.¹⁶

STANDARDIZED METHODS TO ASSESS NAIL PSORIASIS SEVERITY

For standardized assessment of nail psoriasis, most clinical studies use the Nail Psoriasis Severity Index (NAPSI), which allows for objective scaling of the severity of nail psoriasis in an individual nail.¹³ The

index gives each affected nail a score out of 8 total possible points, based on the presence of psoriatic changes in the nail

matrix and nail bed of each of the quadrants of the fingernail (Figure 4).



NAPSI Scoring: For each quadrant, 1 point is given if a nail matrix feature is present, and 1 point is given if a nail bed feature is present for a maximum of 2 points per quadrant.

Nail Matrix (NM)

- Pitting
- Leukonychia
- Crumbling
- Red spots in lunula
- Transverse Grooves
- Trachyonychia

Nail Bed (NB)

- Onycholysis
- Salmon patches/oil drops
- Subungual hyperkeratosis
- Splinter Hemorrhages

Figure 4. Nail Psoriasis Severity Index (NAPSI) Scoring

MEDICAL TREATMENT OF NAIL PSORIASIS

Effective management of nail psoriasis is often complex and challenging for even the most experienced clinician. Currently accepted treatment modalities include topical agents, intralesional injection, systemic medications, and biologic agents. Physical modality approaches such as psoralen plus ultraviolet A, grenz ray, electron beam, pulse dye lasers and superficial radiotherapy (SRT) have also been used in the treatment of nail psoriasis, however, they will not be discussed further in this review, which discusses medical therapies.¹³ When

selecting a regimen, due consideration must be given to the types of nail changes, the locations and extent of nail unit involvement, and the severity of cutaneous or joint manifestations. The patient's ability to tolerate the medication(s) used and adhere to long-term treatment are also important factors as clinical improvement of nail disorders is not immediate due to the slow rate of nail plate growth. In addition, cost and insurance coverage can be important considerations, particularly when utilizing more costly therapies over prolonged durations.

If monotherapy does not evoke an adequate response, combination therapies may be employed.²³

Studies evaluating comparative efficacy between treatment modalities are currently very limited. Of the clinical evidence that does exist, much is of low-quality due either to flawed study design, low statistical power, or both.²⁴ This is particularly true for treatment options such as topical, intralesional, and radiation therapy. This is partially due to the slow rate of nail growth, which leads to several months of turnaround in evaluating the maximum treatment response to a particular agent.²⁵ In addition, treatment results are not reported in a standardized fashion, making comparisons and meta-analyses problematic. In lieu of the limited guidelines available, we will attempt to provide a treatment overview, based on a review of the current literature, to guide clinicians in the medical management of nail psoriasis.

TOPICAL THERAPY APPROACHES

For isolated nail psoriasis patients without cutaneous or joint involvement, topical therapy is considered a safe and effective initial treatment option. Topical agents can also be viable options for any psoriasis patients with mild psoriatic nail involvement, or as an adjunct to a systemic or biologic agent in patients with more severe nail disease. The area of application for any topical agents should be determined by relative nail matrix/nail bed involvement. For improved nail matrix penetration, the topical agent can be applied to the proximal nail folds of the affected nail. For nail bed penetration, the agent should be applied to all the surrounding

edges of the nail plate with the nail plate trimmed to hyponychium prior to application, to maximize drug absorption beneath the nail plate.²³

The most accepted topical therapies for nail psoriasis have historically been high-potency corticosteroids (betamethasone), vitamin D analogs (calcipotriol), or a combination of the two.¹² These can justifiably be considered as primary options. In addition, several small clinical trials have also evaluated the use of other topical agents including tazarotene, anthralin, *Indigo naturalis*, cyclosporine, 5-fluorouracil, and tacrolimus (Table 1). Of these secondary topical agents, anthralin, *Indigo naturalis*, and cyclosporine were noted to show some efficacy in treating nail psoriasis in low-quality clinical trials, and therefore may merit further research in higher quality studies. A key advantage of topical agents is their lower incidence of adverse events compared to other treatment options. This is in part due to the low penetration of these agents into the nail unit, thus the cause of their favorable safety profile also contributes to their limited efficacy. It should also be pointed that some topical therapies, including certain preparations of tar, anthralin, and *Indigo naturalis*, may be too messy to use on the fingernails. *In patients with nail psoriasis involving one or a few fingernails, intralesional corticosteroid therapy is a therapeutic option modality that may be used to induce adequate temporary remission.* Intralesional corticosteroid injections deliver the anti-inflammatory agent more directly to sites of psoriatic inflammation in the nail matrix and nail bed compared to topical treatment.

Table 1. Select literature data on topical treatments for nail psoriasis

Treatment	Study Design	Results	Adverse Effects	Impressions
Clobetasol (8%) nail lacquer ²⁶	2 Randomized, double-blind placebo-controlled studies at two centers with 26 patients in study A and 15 in study B. Study A: Each patient was treated with either clobetasol nail lacquer or placebo lacquer. Study B: Each patient applied clobetasol to one hand and placebo to the contralateral hand.	69% of treatment group patients in study A showed significant improvement compared to the control group, while 80% of patients in study B showed significant improvement in the treated hand. No improvement was seen in 27% of treated patients in study A, and 13% of the treated hand for patients in study B.	None Reported	Nail lacquer is an optimal vehicle to increase clobetasol penetration transungually and is well-tolerated by patients.
Clobetasol (.05% vs. 1% vs. 8%) nail lacquer ²⁷	Prospective, randomized, left-right trial of 15 patients with clobetasol treatment of left hand twice weekly for 16 weeks and no treatment of right hand (control).	8% Clobetasol group showed significant improvement in NAPSI score compared to .05% group, 1% group, and control group.	None Reported	8% Clobetasol nail lacquer is safe and effective.
Calcipotriol (50µg/g) vs. Betamethasone (64mg/g) plus salicylic acid(.03g/g) ²⁸	Randomized, double-blind, comparator trial of 58 patients treated with either calcipotriol monotherapy or betamethasone plus salicylic acid twice daily for 5 months to fingernails and toenails.	After 5 months, calcipotriol group showed 49.2% (fingernails) and 40.7% (toenails) reduction in subungual hyperkeratosis compared to 51.7% (fingernails) and 51.9% (toenails) reduction seen in betamethasone plus salicylic acid group.	None Reported	Calcipotriol may be a safer alternative for treatment of subungual hyperkeratosis than betamethasone plus salicylic acid because the long-term treatment required may lead to greater adverse effects from the topical steroid.
Calcipotriol (.005%) plus betamethasone (.05%) QD vs. Calcipotriol (.005%) BID ²⁹	Randomized, investigator-blind, comparator trial of 32 patients with application of either calcipotriol plus betamethasone once daily or calcipotriol alone twice daily for 12 weeks.	Both groups showed at least moderate improvement after 12 weeks, however no statistical difference in efficacy between the 2 groups. Only 26% of patients in calcipotriol group applied twice daily as instructed, while majority instead applied only once daily.	None Reported	Despite similar efficacy, calcipotriol plus betamethasone therapy once daily may be preferred due to better compliance compared to twice daily calcipotriol monotherapy. Both treatments reduced oil drop discoloration, but nail crumbling worsened over treatment course.
Calcipotriol plus betamethasone ³⁰	Open-label trial of 22 patients with application of ointment daily at bedtime for 12 weeks.	Mean NAPSI score was 5.8 pre-treatment and dropped to 1.6 post-treatment (76% reduction).	Mild irritation of fingertips in 2 treated patients (self-limiting)	Calcipotriol plus betamethasone ointment daily can significantly improve hyperkeratosis and onycholysis, with moderate improvement of oil drops, and slight improvement of pitting.
Tazarotene (0.1%) gel ³¹	Randomized, double-blind, vehicle-controlled, parallel-group trial of 31 patients treated with either tazarotene or vehicle gel applied nightly for 24 weeks in 2 fingernails (1 occluded and 1 nonoccluded).	Treatment group had significantly greater reduction in onycholysis in weeks 4 and 12 (occluded and nonoccluded), and in pitting at week 24 (occluded only).	Mild to moderate events (peeling of proximal nail fold skin, irritation of skin on finger, periungual irritation, paronychia, and erythema of the proximal nail fold) in 5 out of 21 treated patients.	Evening applications of tazarotene (0.1%) can significantly reduce onycholysis and pitting, with few mild to moderate side effects.
Anthralin (0.4-2%) in petrolatum ³²	Open-label trial of 20 patients with ointment application to nail bed for 30 minutes per day for 5 months.	12 patients (60%) showed moderate to obvious improvement, and 4 patients (12%) showed no response.	Reversible nailplate pigmentation which is reduced by applying 10% triethanolamine cream.	Anthralin (0.4-2%) is most effective for onycholysis, pachyonychia, and pitting.
Indigo naturalis formulation (Lindioil) ³³	Randomized, observer-blind, vehicle-controlled, left-right trial of 31 patients with Lindioil treatment to one hand and olive oil (control) to contra-lateral hand, twice daily for 30 minutes for 12 weeks.	After 12 weeks, treatment group showed 49.8% reduction in NAPSI score for entire hand, and 59.3% reduction in NAPSI for most affected nail, while control group showed 22.9% and 16.3% reduction respectively.	None Reported	<i>Indigo naturalis</i> is safe and effective.
Cyclosporin solution (70% dissolved in maize oil) ³⁴	Randomized, prospective placebo-controlled study of 16 patients treated with either cyclosporin solution or maize oil (control) daily for 12 weeks.	Treatment group had complete remission in 3 of 8 patients and significant improvement in 5 of 8 patients, while control group showed slight improvement in 1 of 8 patients, and minimal to no improvement in 7 of 8 patients.	None Reported	Topical cyclosporin can significantly improve onycholysis and hyperkeratosis with no reported adverse events and no cyclosporin detectable in serum.
Belanx (urea, propylene glycol) plus 5-Fluorouracil (1%) vs. Belanx monotherapy ³⁵	Randomized, double-blind, left-right trial of 57 patients treated with either Belanx plus 5-FU or Belanx alone, daily for 12 weeks.	Both groups showed statistically significant improvement from baseline, however, no statistically significant difference was found between the two groups.	Nail pain, swelling, discoloration, inflammation, onycholysis, or perforation were reported 9 times by 6 patients in the Belanx plus 5-FU group, while no adverse events were reported in the Belanx monotherapy group.	5-Fluorouracil (1%) added to Belanx lotion does not improve the efficacy in treatment of nail psoriasis, compared to Belanx lotion alone, and is associated with a higher incidence of adverse events.

INTRALESIONAL CORTICOSTEROID INJECTION

In patients with nail psoriasis involving one or a few fingernails, intralesional corticosteroid therapy is a therapeutic option modality that may be used to induce adequate temporary remission. Intralesional corticosteroid injections deliver the anti-inflammatory agent more directly to sites of psoriatic inflammation in the nail matrix and nail bed compared to topical treatment. Intralesional therapy is typically limited to corticosteroid injection, most commonly triamcinolone acetonide.³⁶

Treatment protocols for intralesional triamcinolone vary greatly in the literature. The optimal injection site for nail matrix psoriasis is the proximal nail fold (PNF), while the lateral nail folds (LNF) and the hyponychium are the recommended injection sites for treatment of nail bed psoriasis.³⁷ Among different studies, concentrations have varied from 1 mg/mL to 10 mg/mL, with ranges of 0.1 mL to 0.3 mL per injection. In addition, frequency of injections per visit, and treatment intervals also vary widely, ranging from a single injection to monthly injections.¹²

The major adverse effect limiting the use of intralesional corticosteroid therapy is the pain associated with treatment. This pain can be effectively managed with local anesthesia or a digital nerve block prior to treatment. An ice pack may also be applied prior to injection to reduce pain. Another potential side-effect of injection, which occurs more commonly with injections beneath the nail bed, is the occurrence of subungual hematomas. These,

however, are primarily of cosmetic concern and will disappear over time. More worrisome complications associated with recurrent intralesional corticosteroid treatment are reversible atrophy at the injection site and permanent atrophy of the distal phalanx.³⁶

SYSTEMIC THERAPY APPROACHES

For patients with moderate to severe nail psoriasis with cutaneous an/or joint manifestations, systemic therapy may be beneficial to induce improvement of the psoriatic lesions. Though systemic therapies are generally avoided in most cases of localized psoriasis, they may be considered in patients with severe isolated nail psoriasis that is refractory to the previously described treatment modalities, especially fingernail disease. Compared to the previously described locally acting agents, systemic therapies have the advantage of acting at all sites of psoriatic inflammation concurrently, leading to improved efficacy in treating multiple psoriatic lesions. However, due to widespread dissemination, these therapies can also cause systemic adverse events. For this reason, the systemic agents are often reserved for patients suffering significant quality of life impairment from nail psoriasis. The systemic agents used in the treatment of nail psoriasis include: methotrexate, cyclosporine, acitretin, and apremilast.²³ Evidence supporting the use of these systemic agents lags behind that of certain biologic agents.

The results of several major studies of systemic agents for nail psoriasis indicate that each of the various agents

have at least some efficacy in treating nail psoriasis (Table 2). However, due to the general paucity of high-quality research on the topic, it is difficult to compare the efficacy and tolerability of any one agent in relation to the others. This is further complicated by the variation in dosages and dosing intervals employed for specific agents in the few studies available. One ranking of systemic therapies created by the Medical Board of the National Psoriasis Foundation, recommended methotrexate with greater enthusiasm, followed by acitretin, and finally apremilast.⁴³ It should be noted that acitretin commonly causes thinning of the nail plate and can also be associated with onychomadesis. This review group did not include cyclosporine as one of the recommended systemic agents, possibly due to its greater side-effect profile in comparison to the safety and efficacy of the biologics. Moreover, the size and quality of clinical trials assessing nail outcomes in patients on biologic therapies exceeds what has been reported with other therapies. Based on the conflicting trial data reported for systemic agents, it is possible that certain agents are more efficacious or better tolerated than others.

BIOLOGIC AGENTS

For the treatment of nail manifestations from moderate to severe psoriasis and/or psoriatic arthritis, biologic agents have proven to be highly effective options to induce improvement of nail psoriasis in most patients. The past decade has brought significant

advances in the treatment of cutaneous, joint, and nail psoriasis. The most important of these advances has been the expansion of biologic response modifiers (biologics). Through their direct inhibition of specific cytokines involved in psoriatic inflammation, the biologics have demonstrated greater treatment efficacy in higher-quality clinical trials than the other treatment modalities for nail psoriasis (Table 3).⁵⁶ The biologics available for psoriasis and psoriatic arthritis target several different inflammatory mediators including TNF α (infliximab, etanercept, adalimumab, and golimumab), IL-17 (secukinumab, ixekizumab), and IL-12/23 (ustekinumab). In addition, a janus kinase (JAK) inhibitor (tofacitinib) has also shown benefit in phase III trials, though it has not yet been approved in the United States for psoriasis.⁵⁵

While many biologics have demonstrated favorable clinical efficacy, selection of the best biologic agent for a specific patient can still prove difficult. A few attempts have been made to rank the efficacy and safety of biologic agents used in the treatment of nail psoriasis, most notably by the Medical Board of the National Psoriasis Foundation. For patients with moderate to severe symptoms throughout the skin, nails, and joints; the board recommended adalimumab, etanercept, and ustekinumab with high enthusiasm. They also recommended infliximab, though with less enthusiasm.⁴³ Of note, data from the more recent anti-IL-17 clinical trials were not evaluated in these recommendations. However, results from phase II and III clinical trials for secukinumab, ixekizumab and brodalumab are very promising for nail psoriasis. Likewise, early indications are

that the new anti-IL-23 antibodies like guselkumab will likewise show significant efficacy for nail psoriasis. While this ranking provides a basic framework to aid in biologic agent selection, due to the high cost of these medications, the patient's insurance coverage and any financial concerns should also be taken into consideration. In addition, long-term tolerability is also a crucial factor to consider, as the medications do have risk of potential systemic side-effects. Most commonly, patients experience increased infection rates due to the blocking of inflammatory mediators, however infusion reactions, mild systemic effects, and even serious anaphylactic reactions are also possible with these medications. Reactivation or infection with tuberculosis is also a serious potential side-effect, thus meriting annual Tb screening for patients taking a biologic agent.²³ The possibility of adverse effects must be appropriately weighed against the potential benefits of therapy, and thus in most cases, patients with mild disease would not be candidates to receive biologics. Despite these possible adverse effects, biologics do have safety advantages over some of the oral systemic therapies. For example, they are not associated with the liver and bone marrow toxicity of methotrexate, or the nephrotoxicity of cyclosporine.

PATIENT EDUCATION SUGGESTIONS FOR NAIL PSORIASIS

One of the most important, yet often overlooked aspects of nail psoriasis treatment is quality patient education. Patients should be coached on the relapsing nature of the disease prior to treatment, to optimize long-term adherence and maintain adequate remission. Avoiding physical trauma to the nails can also prevent psoriatic inflammation, which can be exacerbated through a similar mechanism seen in the Koebner phenomenon. In addition, chemical trauma should also be limited by avoiding exposure to known irritants and caustic substances.⁵⁷ Keeping nails cut short can prevent inadvertent onycholysis in patients with ongoing nail bed inflammation, and if onycholysis has already occurred, short nails can prevent trapping of debris beneath the nail plate.²⁵

Table 2. Select literature data on systemic treatments for nail psoriasis

Treatment	Study Design	Results	Adverse Effects	Impressions
Infliximab (5 mg/kg) ⁴⁴	Phase III, randomized, double-blind, placebo-controlled trial of 378 patients treated with either infliximab or placebo at weeks 0, 2, 6, and every 8 weeks to week 46. The placebo group crossed over to infliximab at week 24.	Complete clearance of nail disease was seen in 44.7% of patients by week 50 in infliximab group, compared to 5.1% in placebo group. At week 24, mean NAPSI score reductions were 57.2% in infliximab group and -7.7% in placebo group.	At least one adverse event was reported by 82% of the infliximab group. The most common event was infection, seen in 42% of treatment group, followed by headache (14%). 9% of patients withdrew from the study due to adverse events.	Infliximab (5mg/kg) QD therapy can lead to a drastic and sustainable reductions in both nail matrix and nail bed features of nail psoriasis.
Infliximab (5 mg/kg) ⁴⁵	Retrospective analysis of 240 nail psoriasis patients from the EXPRESS study who had an initial response to infliximab and continued therapy up to week 46. Patients received IV infusions at weeks 0, 2, and 6 for induction, and subsequently every 8 weeks for maintenance.	In the infliximab treated patients, mean NAPSI scores had decreased by 28.3% at week 10, 61.4% at week 24, and 67.8% at week 50. Those patients achieving at least a 75% improvement in PASI score by week 50, had a 78.2% reduction in mean NAPSI score.	27 of 240 (11.3%) patients discontinued treatment prior to week 46 due to adverse events which were not reported.	Infliximab (5 mg/kg) induction and maintenance therapy led to sustained improvements in mean NAPSI scores at 1 year. Improvement in nail bed pathology occurred earlier and to a greater extent compared to nail matrix manifestations.
Etanercept (25 mg subcutaneously twice weekly), and etanercept (50 mg subcutaneously twice weekly for 12 weeks or until response) ⁴⁶	Randomized, multi-center, open-label study of 562 patients treated with etanercept 25 mg twice weekly or etanercept 50 mg twice weekly.	In the combined analysis of both groups at 12 and 54 weeks, the mean NAPSI score decreased 28.9% and 51%, respectively. By 54 weeks, 30% of patients had a complete resolution of symptoms.	None Reported	Etanercept treatment significantly improved symptoms, quality of life, and psychosocial function in nail psoriasis patients.
Adalimumab (40 mg) ⁴⁷	Prospective, open-label, uncontrolled study of 442 patients, of which 164 patients had psoriatic arthritis and psoriatic nail manifestations (NAPSI ≥ 10) treated with adalimumab 40 mg for 12 weeks.	Of the 164 patients with baseline NAPSI scores ≥ 10, 84 patients (54.2%) had over 50% improvements in their NAPSI score by week 12.	26 of 442 (5.9%) patients withdrew from the study due to adverse events, including 4 infections.	Adalimumab is an effective therapy for the treatment of nail psoriasis in patients with psoriatic arthritis. Patients with greater clinical response included those with greater pain, those not treated with systemic glucocorticoids, those with lower physical impairment and males.
Adalimumab vs. Etanercept vs. Infliximab ⁴⁸	Prospective, open-label study of 60 patients treated with either adalimumab, etanercept, or infliximab for 24 weeks.	For the adalimumab group, the mean NAPSI score was 33.1 at week 0, 21 at week 14, and 11.4 at week 24. For the etanercept group, the NAPSI was 34.8 at week 0, 23.6 at week 14, and 10.6 at week 24. For the infliximab group, the mean NAPSI was 33.3 at week 0, 14.9 at week 14, and 3.1 at week 24.	None Reported	Infliximab had the greatest improvement in NAPSI at week 14, and the greatest total improvement at week 24, compared to adalimumab and etanercept.
Golimumab (50 mg vs. 100 mg) every 4 weeks ⁴⁹	Phase III, randomized, double-blind, placebo-controlled trial of 405 psoriatic arthritis patients treated with either golimumab 50 mg, golimumab 100 mg, or placebo, every 4 weeks. Certain patients in the placebo group were changed to golimumab 50 mg at week 16 or at week 24, while some patients in golimumab 50 mg were switched to 100 mg.	At week 52, the mean NAPSI score had decreased by 51.6% for golimumab 50 mg group, 65.8% for golimumab 100 mg group, and 56.2% in the placebo group. Note that the placebo group includes patients switched to golimumab 50 mg at week 16 or week 24.	Most commonly upper respiratory infections and nasopharyngitis at similar rates in all treated patients.	Golimumab is a safe and effective therapy for nail manifestations of psoriatic arthritis. Note that patients were permitted to continue stable doses of methotrexate and prednisone.
Secukinumab (300 mg vs. 150 mg) ⁵⁰	Phase III, randomized, double-blind, placebo-controlled trial with 198 patients receiving either secukinumab 300mg, secukinumab 150 mg, or placebo for up to 76 weeks.	After 16 weeks, mean reduction in NAPSI score was 45.4% for secukinumab 300mg, 38.9% for secukinumab 150mg, and 11.2% for placebo.	Nasopharyngitis, headache, and upper respiratory infections were the most commonly reported side-effects in treatment groups.	Secukinumab led to the highest efficacy at week 16 out of all prospective, placebo-controlled trials for treatment of nail psoriasis.
Secukinumab (150 mg) in 3 different regimens (single vs. early vs. monthly) ⁵¹	Phase II, randomized, double-blind, placebo controlled trial of 131 patients treated with either secukinumab 150 mg (3 different groups) or placebo up to 12 weeks. The 3 secukinumab regimens consisted of subcutaneous injections at either week 0 only (single), weeks 1-4 (early), or at weeks 0, 4, and 8 (monthly).	At week 12, the composite fingernail scores improved by 19.1% in the early regimen group, by 10.6% in the monthly regimen group, and by 3.7% in the single dose group. The fingernail scores worsened by 14.4% in the placebo group at 12 weeks.	None Reported	Secukinumab 150 mg given at monthly or weekly intervals is effective in the short-term for treatment of nail psoriasis, however further research is necessary to evaluate efficacy over a longer term.
Ixekizumab (10 mg, 25 mg, 75 mg, 150 mg) subcutaneously once weekly ⁵²	Phase II randomized, double-blind, placebo-controlled trial of 142 patients treated with either ixekizumab 10 mg, 25 mg, 75 mg, 150 mg, or placebo once weekly at weeks 0, 2, 4, 8, 12, and 16.	At 12 weeks, the mean NAPSI score had decreased by 49.3% for 150 mg, 57.1% for 75 mg, and 24.0% for 25 mg. The mean NAPSI score increased by 14.3% in the 10 mg group, and increased by 6.8% in the placebo group.	Infections which did not appear dose-dependent.	Ixekizumab 75 mg and 150 mg injections once weekly are safe and efficacious for the treatment of nail psoriasis.
Ustekinumab (45 mg vs. 90 mg) ⁵³	Phase III, randomized, double-blind, placebo-controlled trial of 766 patients treated with either ustekinumab 45mg, ustekinumab 90mg, or placebo in 4 distinct treatment periods, with the placebo group crossing-over to ustekinumab 45 mg at 12 weeks.	At week 12, the baseline NAPSI score decreased by an average of 26.7% in patients receiving ustekinumab 45mg, 24.9% with ustekinumab 90mg, and 11.8% with placebo. By week 24, ustekinumab 45mg had decreased to 46.5% and ustekinumab 90 mg had decreased to 48.7%.	None Reported	Ustekinumab significantly improves nail psoriasis for up to 1 year with maintenance treatment.
Ustekinumab (45 mg vs. 90 mg) ⁵⁴	Phase III/III, randomized, double-blind, placebo-controlled trial of 158 patients treated with either ustekinumab 45mg, ustekinumab 90mg, or placebo.	At week 64, the mean NAPSI score had decreased by 56.6% in the ustekinumab 45mg group, and by 67.8% in the ustekinumab 90mg group.	Nasopharyngitis, increased triglycerides, increased CPK, and seasonal allergy were the most commonly reported adverse events in both treatment groups, at comparable rates in both groups. Infection rates were 64.6% (45mg) and 73.3% (90mg) at 72 weeks.	Ustekinumab was generally well-tolerated and efficacious in the treatment of nail psoriasis.
Tofacitinib (5 mg BID vs. 10 mg BID) ⁵⁵	2 Identical phase III, randomized, double-blind, placebo-controlled trials of 1,859 and 1,196 patients, respectively, with patients treated with tofacitinib 5 mg, tofacitinib 10 mg, and placebo.	At week 16, the mean NAPSI score had decreased by 7.9% with tofacitinib 5mg and by 10.5% with tofacitinib 10mg, compared to 0.4% with placebo. By week 52, the mean NAPSI score had decreased by 65.6% with tofacitinib 5mg and by 75.5% with tofacitinib 10mg.	None specifically noted, however it was reported that low rates of serious adverse events were seen across all groups.	Tofacitinib 5mg BID and 10mg BID both improved nail psoriasis compared to psoriasis in 16 weeks, and improvements sustain up to 1 year with maintenance therapy.

Table 3. Select literature data on systemic treatments for nail psoriasis

Treatment	Study Design	Results	Adverse Effects	Impressions
Methotrexate (15 mg) vs. Cyclosporin (5 mg/kg) ³⁸	Prospective comparator trial of 37 patients treated with methotrexate (15 mg weekly) or cyclosporin (5 mg/kg daily) for 24 weeks.	At 24 weeks, mean reduction in NAPSI score was 43.3% for the methotrexate group, and 37.2% for the cyclosporin group.	2 patients in the methotrexate group experienced nausea and telogen effluvium. In the cyclosporin group, 3 patients experienced adverse effects of hirsutism, hyperlipidemia, and menstrual abnormalities, respectively.	No significant difference was found in mean NAPSI improvement between the two groups, however, a significant improvement was seen with methotrexate for nail matrix findings, and cyclosporin for nail bed findings.
Briakinumab (200 mg then 100 mg) vs. Methotrexate (5 mg to 25 mg) ³⁹	Phase III, randomized double-blind trial of 317 patients with 154 patients treated with briakinumab 200 mg at weeks 0 and 4, followed by 100 mg every 4 weeks from week 8 through week 48, and 163 patients treated with methotrexate 5 mg to 25 mg plus 5 mg folate per week.	Baseline mean NAPSI scores were 4.8 for briakinumab group and 4.8 for methotrexate group. By week 24, mean NAPSI scores had improved to 2.1 for briakinumab and 3.0 for methotrexate. By week 52, mean NAPSI scores had improved to 1.2 for briakinumab, however the mean NAPSI score for methotrexate remained at 3.0.	Most commonly nasopharyngitis, headache, diarrhea, and nausea in the briakinumab group. Most commonly nasopharyngitis, headache, and nausea in the methotrexate group. 7.8% of patients in briakinumab discontinued treatment due to adverse events, compared to 6.1% in methotrexate group.	Briakinumab had greater efficacy for the treatment nail psoriasis compared to methotrexate, however serious infections and cancer were more frequent with briakinumab (not significant).
Cyclosporin (low-dose) vs. Etretinate ⁴⁰	Multi-center, randomized comparator trial of 210 patients receiving either cyclosporin or etretinate, daily for 10 weeks (phase 1). After 10 weeks (phase 2), the cyclosporin patients were randomly assigned to taper the drug for 12 weeks, or replace immediately with topical anthralin. All patients in the etretinate group were switched to anthralin after 10 weeks.	After 10 weeks, mean NAPSI scores decreased by 71% in the cyclosporin group and 47% in the etretinate group. After 22 weeks, relapse rates were significantly higher in cyclosporin patients who were switched to anthralin at week 10, compared to patients who continued receiving tapering cyclosporin.	Diarrhea, headache, leg cramps, fatigue, and peripheral edema were the most common adverse effects of cyclosporin, seen in 32% of patients. Cheilitis, dry mouth, and skin exfoliation were the most common adverse effects of etretinate, seen in 57% of patients.	Low-dose (2.5 mg/kg/day) cyclosporin therapy is highly effective and well-tolerated, compared to etretinate. Remission of psoriatic lesions can be better maintained by tapering the drug rather than discontinuing treatment immediately.
Acetretin ⁴¹	Prospective, open-label uncontrolled study of 36 isolated nail psoriasis patients treated with acetretin (0.2 to 0.3 mg/kg) daily for 6 months.	At 6 months, mean NAPSI scores decreased by 41%, with complete clearance of nail dystrophy in 9 of 36 patients (25%).	1 patient experienced severe dryness of periungual skin and multiple pyogenic granulomas. No other events reported.	Low-dose acetretin showed NAPSI score improvements comparable to biologic therapies, with lower rates of side effects.
Apremilast (30 mg BID) ⁴²	Phase III, randomized, double-blind, placebo-controlled trial of 1255 patients treated with either apremilast or placebo. At week 16, patients in the placebo group were switched to apremilast through week 32.	At week 16, 22.5% reduction in NAPSI score in treatment group, compared to a 6.5% increase in NAPSI in placebo group.	Reported as mild to moderate in severity, with no increase in severity over time and no new adverse events with continued apremilast exposure.	Apremilast 30 mg BID can significantly reduce the severity of nail psoriasis with continuous improvements sustained for duration of treatment.

CONCLUSION

Up to 80-90% of patients suffering from psoriasis will eventually experience nail dystrophy associated with their disease.^{6,7} Therefore, it is important for clinicians to be able to diagnose nail psoriasis clinically, through observation for classic nail matrix and nail bed manifestations. Nail matrix manifestations include pitting, leukonychia, red spots in the lunula, and nail plate crumbling. These may be found alongside the nail bed changes which include onycholysis, salmon patches (oil drop), subungual hyperkeratosis, and splinter hemorrhages.¹³ Early recognition of nail

disease is important both to prevent long-term physical and psychosocial sequelae, and because growing evidence supports that the presence of nail psoriasis in a patient may be used as a predictor for the development of psoriatic arthritis.²² Following diagnosis of nail psoriasis, the clinician may create a treatment regimen from the various available topical, intralesional, systemic, and biologic agents. Treatment selection for nail psoriasis is a complex undertaking, but can be conceptualized as a spectrum based on the severity of disease present throughout the body. Treatment for mild nail psoriasis is

generally initiated with topical therapy consisting of potent corticosteroids, vitamin D analogs (calcipotriol), or both. For lesions refractory to topical therapy, or for isolated fingernails, intralesional corticosteroid injection is a possible next step in treatment. For more severe nail psoriasis with cutaneous and/or joint manifestations, systemic therapy may also be beneficial.¹² With the advent of new pharmaceutical advances however, the standard of care for severe nail psoriasis is shifting from the systemic agents to the generally more effective biologics.²³ Further clinical research is still needed to create more in-depth treatment protocols for nail psoriasis, however, the future is optimistic for psoriasis patients, as new advances in medicine will continue to allow for safer and more targeted anti-psoriatic treatment.

Conflict of Interest Disclosures: Parth Desai has no conflicts of interest to disclose. Dr. Mark Lebwohl is an employee of Mount Sinai, which receives research funds from Amgen, Anacor Pharmaceuticals Inc, Boehringer Ingelheim, Celgene, Eli Lilly and Company, Janssen Biotech, Kadmon Corporation, LEO Pharmaceuticals, MedImmune, Novartis Pharmaceuticals Corporation, Pfizer, Sun Pharmaceuticals Industries Ltd, and Valeant Pharmaceuticals. Dr. Del Rosso is a consultant, investigator, and/or speaker for Allergan, Aqua/Almirall, Bayer, BioPharmX, Celgene, Cipher (Innocutis), Cutanea, Dermira, Ferndale, Foamix, Galderma, Genentech, Innovaderm, LeoPharma, Novan, Pfizer (Anacor), Pharmaderm, Promius, Regeneron, Sanofi/Genzyme, Sebacia, SunPharma, Taro, Unilever, Valeant (Ortho Dermatologics), and Viamet.

Funding: none.

Corresponding Author:

Parth N. Desai, BS
Mercer University School of Medicine
6800 Gaines Creek Road
Columbus, GA
Desai_pn@med.mercer.edu

References:

1. Prosser J. (2001). The Thick-Skinned Art of John Updike: 'From the Journal of a Leper'. *The Yearbook of English Studies*, 182.
2. Bhutani T, Koo J, Hong J. (2011). Contemporary Diagnosis and Management of Psoriasis. Newtown, Penn: Associates in Medical Marketing Co., Inc.
3. Pariser DM, Bagel J, Gelfand JM, Korman NJ, Ritchlin CT, Strober BE, et al. National Psoriasis Foundation Clinical Consensus on Disease Severity. *Arch Dermatol*. 2007;143:239-24
4. Rachakonda TD, Schupp CW, Armstrong AW. Psoriasis prevalence among adults in the United States. *J Am Acad Dermatol*. 2014;70(3):512-6.
5. Baliwag J, Barnes DH, Johnston A. (2015). Cytokines in psoriasis. *Cytokine*. 73(2), 342–350.
6. Klaassen KM, van de Kerkhof PC, Pasch MC. Nail psoriasis: a questionnaire-based survey. *Br J Dermatol*. 2013;169(2):314-9.
7. Van Der Velden HMJ, Klaassen KM, Peter CM, Van De Kerkhof PC, Pasch MC. Fingernail psoriasis reconsidered: a case-control study *J Am Acad Dermatol*. 69 (2) (2013), pp. 245–252

8. Tan ES, Chong WS, Tey HL. Nail Psoriasis: A Review. *Am J Clin Dermatol*. 2012;13:375–388.
9. Salomon J, Szepietowski JC, Proniewicz A. Psoriatic nails: a prospective clinical study. *J Cutan Med Surg*. 2003;7(4):317–21.
10. Haneke, E. (2015). Anatomy of the nail unit and the nail biopsy. *Seminars In Cutaneous Medicine And Surgery*, 34(2), 95-100.
11. Koo, J. (1996). Population-based epidemiologic study of psoriasis with emphasis on quality of life assessment. *Dermatologic Clinics*, 14(3), 485-496.
12. Jiaravuthisan, MM, Sasseville D, Vender RB, Murphy F, Muhn CY. (2007). Psoriasis of the nail: anatomy, pathology, clinical presentation, and a review of the literature on therapy. *J Am Acad Dermatol*. 57(1), 1-27.
13. Dogra A, Arora AK. (2014). Nail Psoriasis: The Journey So Far. *Indian Journal Of Dermatology*. 59(4), 319-333.
14. Zisova L, Valtchev V, Sotiriou E, Gospodinov D, Mateev G. (2012). Onychomycosis in patients with psoriasis - a multicentre study. *Mycoses*. 55(2), 143-147.
15. Gupta AK, Lynde CW, Jain HC, Sibbald RG, Elewski BE, Daniel C, Summerbell RC. (1997). A higher prevalence of onychomycosis in psoriatics compared with non-psoriatics: a multicentre study. *Br J Dermatol*. 136(5), 786-789.
16. Grover C, Reddy B, Uma Chaturvedi K. (n.d). Diagnosis of nail psoriasis: importance of biopsy and histopathology. *Br J Dermatol*. 153(6), 1153-1158.
17. Batkaeva NV, Korotaeva TV, Batkaev EA. Prevalence of psoriatic arthritis and comorbidities in patients with severe psoriasis: Data of a retrospective analysis of a hospital cohort. *Sovremennâ Revmatologiâ*. Vol 11, Iss 1, Pp 19-22 (2017). 2017;(1) 19.
18. Gladman D, Chandran V. *Psoriatic Arthritis*. Oxford: OUP Oxford; 2009.
19. Williamson L, Dalbeth N, Dockerty JL, Gee BC, Weatherall R, Wordsworth BP. Extended report: nail disease in psoriatic arthritis-clinically important, potentially treatable and often overlooked. *Rheumatology*. 2004; 43: 790–794.
20. Reich K, Kruger K, Mossner R, Augustin M. Epidemiology and clinical pattern of psoriatic arthritis in Germany: a prospective interdisciplinary epidemiological study of 1511 patients with plaque-type psoriasis. *Br J Dermatol*. 2009;160(5):1040–7.
21. Gudjonsson J, Karason A, Antonsdottir A, Runarsdottir E, Gulcher J, Stefansson K, Valdimarsson H. (n.d). HLA-Cw6-positive and HLA-Cw6-negative patients with psoriasis vulgaris have distinct clinical features. *Journal Of Investigative Dermatology*. 118(2), 362-365.
22. Merola JF, Lockshin B, Mody EA. (2017). Switching biologics in the treatment of psoriatic arthritis. *Seminars In Arthritis And Rheumatism*.
23. Pasch M. Nail Psoriasis: A Review of Treatment Options. *Drugs*. April 15, 2016;76(6):675-705.

24. de Vries A. Interventions for nail psoriasis. *Cochrane Database Of Systematic Reviews*. December 11, 2012;(1).
25. Gregoriou S, Kalogeromitros D, Kosionis N, Gkouvi A, Rigopoulos D. Treatment options for nail psoriasis. *Expert Rev Dermatol* 2008;3:339-44.
26. Baran R, Tosti A. Topical treatment of nail psoriasis with a new corticoid-containing nail lacquer formulation. *Journal of Dermatological Treatment*. September 1999;10(3):201.
27. Nakamura RC, Abreu Ld, Duque-estrada B, Tamler C, Leverone AP. Comparison of nail lacquer clobetasol efficacy at 0.05%, 1% and 8% in nail psoriasis treatment: prospective, controlled and randomized pilot study. *An Bras Dermatol*. 2012;87(2):203-11.
28. Tosti A, Piraccini B, Benelli C, et al. Calcipotriol ointment in nail psoriasis: a controlled double-blind comparison with betamethasone dipropionate and salicylic acid. *Br J Dermatol*. October 1998;139(4):655-659.
29. Tzung T, Chen C, Yang C, Lo P, Chen Y. Calcipotriol used as monotherapy or combination therapy with betamethasone dipropionate in the treatment of nail psoriasis. *Acta Dermato-Venereologica*. 2008;88(3):279-280.
30. Rigopoulos D, Gregoriou S, Daniel I,C.R., et al. Treatment of nail psoriasis with a two-compound formulation of calcipotriol plus betamethasone dipropionate ointment. *Dermatology*. 2009;218(4):338-41.
31. Scher RK, Stiller M, Zhu YI. Tazarotene 0.1% gel in the treatment of fingernail psoriasis: A double-blind, randomized, vehicle-controlled study. *Cutis*. 2001;68(5):355-8.
32. Yamamoto T, Katayama I, Nishioka K. Topical anthralin therapy for refractory nail psoriasis. *J Dermatol*. 1998;25(4):231-3.
33. Lin Y, See L, Lin N, et al. Efficacy and safety of Indigo naturalis extract in oil (Lindioil) in treating nail psoriasis: A randomized, observer-blind, vehicle-controlled trial. *Phytomedicine*. June 15, 2014;21:1015-1020.
34. Cannavò S, Guarneri F, Vaccaro M, Borgia F, Guarneri B. Treatment of psoriatic nails with topical cyclosporine: a prospective, randomized placebo-controlled study. *Dermatology (Basel, Switzerland)*. 2003;206(2):153-156.
35. de Jong E, Menke H, van Praag M, van De Kerkhof P. Dystrophic psoriatic fingernails treated with 1% 5-fluorouracil in a nail penetration-enhancing vehicle: a double-blind study. *Dermatology (Basel, Switzerland)*. 1999;199(4):313-318.
36. de Berker D. Management of psoriatic nail disease. *Semin Cutan Med Surg*. 2009;28(1):39-43.
37. Edwards F, de Berker D. Nail psoriasis: clinical presentation and best practice recommendations. *Drugs [serial online]*. December 3, 2009;69(17):2351-2361.

38. Gümüşel M, Özdemir M, Mevlitoğlu I, Bodur S. Evaluation of the efficacy of methotrexate and cyclosporine therapies on psoriatic nails: a one-blind, randomized study. *Journal of the European Academy Of Dermatology And Venereology*. September 2011;25(9):1080-1084.
39. Reich K, Langley R, Valdes J, et al. A 52-Week Trial Comparing Briakinumab with Methotrexate in Patients with Psoriasis. *NEJM*. October 27, 2011;365(17):1586-1596.
40. Mahrle G, Schulze H, Färber L, Weidinger G, Steigleder G, other multicenter c. Low-dose short-term cyclosporine versus etretinate in psoriasis: Improvement of skin, nail, and joint involvement. *J Am Acad Dermatol*. January 1, 1995;32:78-88.
41. Tosti A, Ricotti C, Romanelli P, Cameli N, Piraccini B. Evaluation of the Efficacy of Acitretin Therapy for Nail Psoriasis. *Arch Dermatol*. March 2009;145(3):269-271.
42. Rich P, Gooderham M, Crowley J, et al. Original article: Apremilast, an oral phosphodiesterase 4 inhibitor, in patients with difficult-to-treat nail and scalp psoriasis: Results of 2 phase III randomized, controlled trials (ESTEEM 1 and ESTEEM 2). *J Am Acad Dermatol*. September 1, 2015.
43. Crowley J, Weinberg J, Wu J, Robertson A, Van Voorhees A. Treatment of Nail Psoriasis Best Practice Recommendations From the Medical Board of the National Psoriasis Foundation. *JAMA Dermatol*. n.d.;151(1):87-94.
44. Rich P, Griffiths C, Guzzo C, et al. Report: Baseline nail disease in patients with moderate to severe psoriasis and response to treatment with infliximab during 1 year. *J Am Acad Dermatol*. January 1, 2008;58:224-231.
45. Reich K, Ortonne J, Griffiths C, et al. Skin and Nail Responses after 1 Year of Infliximab Therapy in Patients with Moderate-to-Severe Psoriasis: A Retrospective Analysis of the EXPRESS Trial. *Dermatology*. 2010;221(2):172-178.
46. Luger T, Barker J, Boggs R, et al. Sustained improvement in joint pain and nail symptoms with etanercept therapy in patients with moderate-to-severe psoriasis. *Journal of the European Academy of Dermatology and Venereology*. August 2009;23(8):896-904.
47. Van den Bosch F, Manger B, Kupper H, et al. Effectiveness of adalimumab in treating patients with active psoriatic arthritis and predictors of good clinical responses for arthritis, skin and nail lesions. *Annals of The Rheumatic Diseases*. February 2010.;69(2):394-399.
48. Saraceno R, Pietroleonardo L, Mazzotta A, Zangrilli A, Bianchi L, Chimenti S. TNF- α antagonists and nail psoriasis: an open, 24-week, prospective cohort study in adult patients with psoriasis. *Expert Opinion On Biological Therapy*. April 2013;13(4):469-473.
49. Kavanaugh A, van der Heijde D, Beutler A, et al. Golimumab in psoriatic arthritis: one-year clinical efficacy, radiographic, and safety results from a phase III, randomized, placebo-controlled

trial. *Arthritis and Rheumatism*. August 2012;64(8):2504-2517.

50. Reich K, Sullivan J, Arenberger P, et al. Secukinumab is effective in subjects with moderate to severe plaque psoriasis with significant nail involvement: 16 week results from the TRANSFIGURE study. Presented at: 23rd World Congress of Dermatology; Vancouver, Canada; June 8-15, 2015.

51. Paul C, Reich K, Papavassilis C, et al. Secukinumab improves hand, foot and nail lesions in moderate-to-severe plaque psoriasis: subanalysis of a randomized, double-blind, placebo-controlled, regimen-finding phase 2 trial. *Journal of the European Academy of Dermatology and Venereology*. December 2014;28(12):1670-1675.

52. Leonardi C, Matheson R, Banerjee S, et al. Anti-interleukin-17 monoclonal antibody ixekizumab in chronic plaque psoriasis. *NEJM*. March 29, 2012;366(13):1190-1199.

53. Rich P, Bourcier M, Poulin Y, et al. Ustekinumab improves nail disease in patients with moderate-to-severe psoriasis: results from PHOENIX 1. *Br J Dermatol*. February 2014;170(2):398-407.

54. Igarashi A, Kato T, Kato M, Song M, Nakagawa H. Efficacy and safety of ustekinumab in Japanese patients with moderate-to-severe plaque-type psoriasis: Long-term results from a phase 2/3 clinical trial. *Journal of Dermatology*. March 2012;39(3):242-252.

55. Merola J, Elewski B, Tatulych S, Lan S, Tallman A, Kaur M. Efficacy of tofacitinib

for the treatment of nail psoriasis: Two 52-week, randomized, controlled phase 3 studies in patients with moderate-to-severe plaque psoriasis. *J Am Acad Dermatol*. April 7, 2017.

56. de Berker D. Biologics in nail psoriasis. *Br J Dermatol*. February 2014;170(2):236-237.

57. Manhart R, Rich P. Nail psoriasis. *Clinical And Experimental Rheumatology*. 33(5):S7-S13.