

BRIEF ARTICLES

Palmoplantar Pityriasis Rosea

Aurel Apple, BA¹, Ann Lin, DO, Angela Kim, DO, MPH², Suzanne Rozenberg, DO², Rachel Kushner, DO²

¹New York Institute of Technology College of Osteopathic Medicine, Port Jefferson, NY

²Department of Dermatology, St. John's Episcopal Hospital, Far Rockaway, NY

INTRODUCTION

Pityriasis rosea (PR) is characterized by a papulosquamous rash with minimal constitutional symptoms. Atypical variants of PR are less easily recognized and constitute about 20% of all reported cases, thus formulating a thorough differential diagnosis is critical in making a proper diagnosis.^{1,2} Many atypical variants of PR have been described including vesicular, unilateral, and inverse PR.³ We describe a 48-year-old male who presented following a traumatic motor vehicle accident with an atypical presentation of palmoplantar PR which mimicked secondary syphilis.

CASE PRESENTATION

A 48-year-old man with Fitzpatrick type IV skin presented with a rash of 2 days duration on his lower back, that spread to his upper back, legs, thighs, arms, neck and torso. He reported right knee abrasion following a pedestrian versus vehicle MVA that he self-treated with triple antibiotic ointment on the right knee. The area then became red, itchy and expanded. He denied any recent viral illnesses or systemic symptoms. The patient reports

monogamous sexual activity with wife for the past few decades. Denies any other sexual encounters.

Physical exam showed erythematous papules and plaques with collarettes of scales on the patient's neck, arms, back, thighs, legs and buttocks (figure 1). A large erythematous scaly plaque was noted on the either side of the right knee, the site of MVA injury (figure 2). The initial diagnosis of PR was made and no initial treatment was provided due to the asymptomatic nature of the skin rash. At the two-week follow up the papulosquamous rash became even more widespread, with more prominent scale and erythema. Moreover, dusky, erythematous, scaly papules and plaques were seen on the palms and soles, raising suspicion for secondary syphilis (figure 3).

Labs for RPR, CBC, CMP, and HIV as well as two punch biopsies were taken from the patient's left upper posterior thigh and right lateral knee with the request for spirochete staining. RPR, with reflex titer and confirmatory testing, was non-reactive and HIV testing was negative. Biopsy of the left upper posterior thigh and right lateral knee showed hyperkeratosis, irregular epidermal hyperplasia, focal mounds of parakeratosis, spongiosis and perivascular inflammatory

Figure 1. Diffuse Erythematous Scaly Papules and Plaques with Collarette of Scales on the Back.

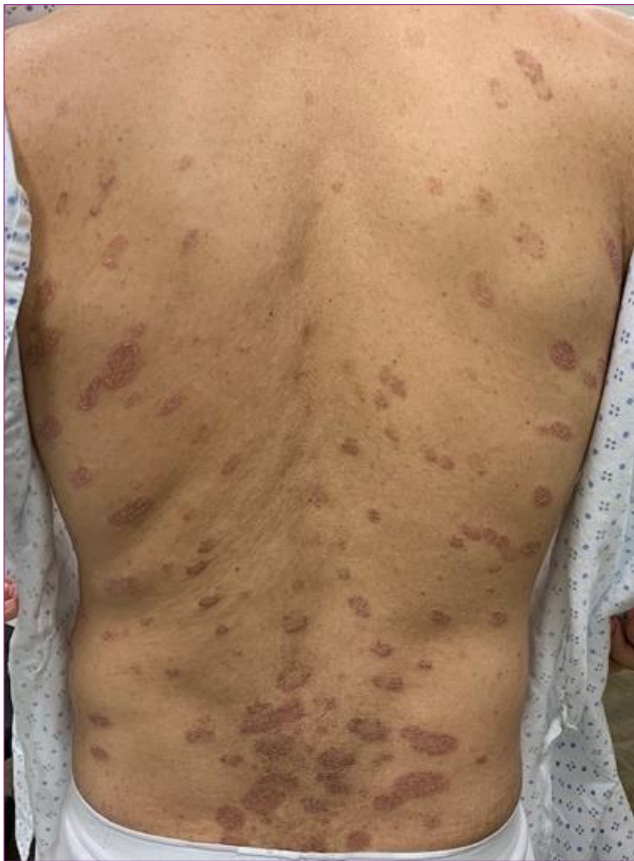

Figure 2- Site of Abrasion from MVA. Lesion with Peripheral Scale Expanded after Application of Triple Antibiotic Ointment.

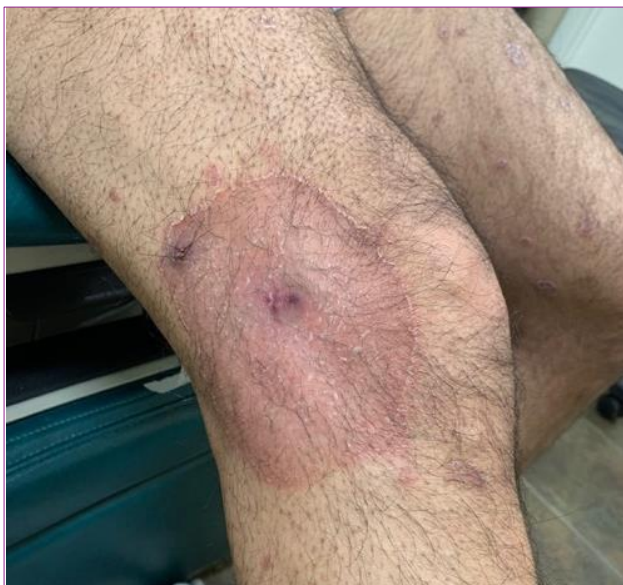
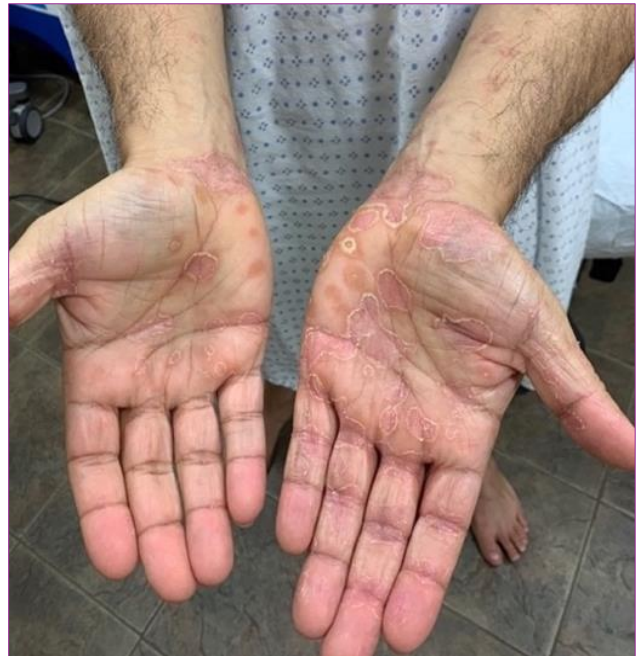
Figure 3- Erythematous Scaly Papules and Plaques on the Palms.



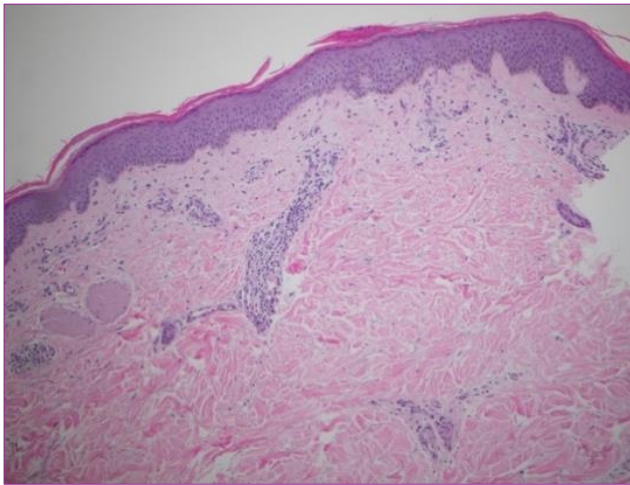
infiltrate of lymphocytes cuffing around the vessels. A few extravasated RBCs were noted as well as presence of focal exocytosis of lymphocytes within the epidermis. Silver staining was negative for spirochetes and PAS was negative for fungal hyphae. The final pathology diagnosis read “mild spongiotic dermatitis possible pityriasis rosea; a drug or viral exanthem is not excluded.”

DISCUSSION

Pityriasis rosea (PR) has been widely documented in literature as an acute papulosquamous skin rash, most commonly affecting children and young adults. Its etiology remains uncertain, but it's believed to be of viral origin.⁴ Typically, PR will first manifest with a “herald patch” which is larger and more conspicuous than later eruptions.¹ Histopathological examination of these lesions shows focal parakeratosis, mild acanthosis, mild spongiosis, papillary dermal

edema with perivascular infiltrates of lymphocytes and histiocytes and focal extravasation of the RBCs.^{1,5}

Figure 4. Punch Biopsy from Left Upper Posterior Thigh. Mild spongiosis in epidermis with mounds of parakeratosis above the stratum corneum. Sparse papillary dermal lymphocytes, perivascular inflammation with lymphocytes. Some extravasated erythrocytes are seen. Silver stain negative for spirochetes. (H&E, 4x)



Atypical presentations of PR are differentiated by their varying morphology, size, distribution, number, site, severity, and course.¹ Our case was atypical in its site of involvement and in its course. Our patient presented with widespread erythematous scaly papules and plaques with palmoplantar involvement. Palmoplantar PR is minimally documented to our knowledge. Different variants of palmoplantar PR have been reported, the first being Bukhari who called for palmoplantar involvement to be included among the known variant forms of PR.⁶

Lesions of secondary syphilis may appear similarly to palmoplantar PR but would also be associated with systemic symptoms such as genital-mucosal involvement and lymphadenopathy.⁷ We ruled out syphilis with a non-reactive rapid plasma reagin (RPR) test. No additional treponemal testing

was performed as the patient did not have health insurance. However, RPR may be negative in syphilis patients with a high treponemal load or with concomitant HIV in prozone effect, but our patient denied any history of sexually transmitted infection and HIV test was negative.⁸ We performed two punch biopsies of papulosquamous lesions on the patient's left upper posterior thigh and right lateral knee.⁸ Biopsies of both the left upper posterior thigh and the right lateral knee revealed patterns more consistent with PR, and silver staining failed to detect any spirochetes.

Additionally, our patient may have exhibited the Koebner Phenomenon, which is the extension of disease process to unaffected skin that is usually preceded by trauma.⁹ While first described in psoriasis, it has since been reported in other diseases including PR.^{9,10} Nwabudike presented a case suggesting PR due to Koebner phenomenon occurring at a site of a routine blood draw in a 35-year-old female patient.⁹ Similar to Nwabudike case, we conjectured this phenomenon possibly occurred in our patient.⁹ The largest initial lesion on our patient's right knee may have been the herald patch that erupted post-traumatically and/or secondary to allergic contact dermatitis to the triple antibiotic cream. Our patient's negative history of a recent viral illness, often an inciting factor for eruptions of PR, further suggests this alternate explanation of his PR onset by the Koebner phenomenon. Other possible causes of PR in our patient include an Id reaction from allergic contact dermatitis of the knee at the original application site of triple antibiotic ointment.

CONCLUSION

The differential diagnoses for papulosquamous palmoplantar lesions

November 2020 Volume 4 Issue 6

include secondary syphilis, palmoplantar psoriasis, dyshidrotic dermatitis, and tinea manus. If clinical history suggest secondary syphilis given a negative RPR, more specific lab results could be obtained. Treponemal tests are more specific, which include fluorescent treponemal antibody absorption (FTA-ABS), microhemagglutination test for antibodies to *T. pallidum* (MHA-TP) and several others. Furthermore, Koebner phenomenon resulting in PR, although not well documented, should be considered as potential instigating factor and may contribute to further understandings of this process.

Acknowledgements: Special thanks and dermatopathology image credits to SJEH Department of Pathology, Sadaf Sheikh, M.D. and Bridge Dermatopathology, Paul Chu, M.D.

Conflict of Interest Disclosures: None

Funding: None

Corresponding Author:

Aurel Apple, BA
College of Osteopathic Medicine
Institute/University/Hospital: New York Institute of
Technology
25 Seaside Drive
Port Jefferson, NY 11777
Phone: 631-848-6477
E-mail: aapple@nyit.edu

References:

1. Kumarasamy RRP. Papular pityriasis rosea with palmar involvement an atypical presentation. *University Journal of Medicine and Medical Specialties* 2017; 3(4).
2. Chuh A, Zawar V, Leet A. Atypical presentations of pityriasis rosea: case presentations. *Journal of the European Academy of Dermatology and Venereology* 2005; 19: 120-126.
3. Deng Y, Li H, Chen X. Palmoplantar pityriasis rosea: two case reports. *Journal of the European Academy of Dermatology and Venereology* 2006; 21(3).
4. Stulberg DL, Wolfrey J. Pityriasis rosea. *American Family Physician* 2004; 69: 87–91.
5. Okamoto H, Imamura S, Aoshima T, et al. Dyskeratotic degeneration of epidermal cells in pityriasis rosea: Light and electron microscopic studies. *British Journal of Dermatology* 1982; 107:189.
6. Bukhari I. Pityriasis rosea with palmoplantar plaque lesions. *Dermatology Online Journal* 2005; 11(1): 27.
7. Baughn RE, Musher DM. Secondary syphilitic lesions. *Clinical Microbiology Reviews* 2005; 18(1): 205-216.
8. Smith G, Holman RP. The Prozone Phenomenon with Syphilis and HIV-1 Co-infection. *Southern Medical Journal* 2004; 97(4): 379-382.
9. Nwabudike LC. Does pityriasis rosea koebnerise? *Our Dermatology Online* 2013; 4(2): 189-190.
10. Weiss G, Shemer A, Trau H. The Koebner phenomenon: review of the literature. *JEADV* 2002; 16: 241-248